

Scrotal Lesions of Metastatic Rectal Adenocarcinoma: Case Report and Literature Review

Mansour Moghimi¹, Amir Aryanfar², Hassanali Vahedian-Ardakani³, Fatemeh Joukar²

¹ Department of Pathology, School of Medicine, Shahid Sadoughi University of Medical Sciences, Yazd, Iran

² School of Medicine, Shahid Sadoughi University of Medical Sciences, Yazd, Iran

³ Department of Hematology, School of Medicine, Shahid Sadoughi University of Medical Sciences and Health Services, Yazd, Iran

Received: 28 Feb. 2018; Accepted: 15 Dec. 2018

Abstract- Secondary scrotal tumors originating from viscera are rare and indicate a poor prognosis. We report a patient who underwent abdominoperineal resection due to his rectal cancer. Tumor recurrence at the surgical site led to prostate involvement. About 1 month after the prostatectomy, scrotal skin metastasis presented as bilateral papulonodular lesions. Finally, brain metastasis occurred and caused his death. Also, several ways by which malignancies can metastasize to scrotum have been discussed.

© 2019 Tehran University of Medical Sciences. All rights reserved.

Acta Med Iran 2019;57(4):262-266.

Keywords: Colorectal cancer; Scrotal lesion; Skin involvement; Metastasis

Introduction

Colorectal cancer, the most common gastrointestinal malignancy, is the third fatal cancer in the U.S. (1,2). About 20% of patients may represent distant metastases at diagnosis, and other 30% may have metastases during their disease course (3-5). These metastases usually involve liver, peritoneum, and lungs (6). On the one hand, metastases of colorectal cancer to the scrotum are rare. Moreover, secondary metastases of the scrotum are also rare. Urinary (7-11), gastrointestinal (12,13), and respiratory (14) systems can be considered as the possible origin of these rare metastases. Here, we explain a 59-year-old man with scrotal metastasis derived from colorectal adenocarcinoma.

Case Report

A 59-year-old man was admitted to our hospital, in September 2010, with a history of polypectomy 5 years earlier. He complained of abdominal pain and rectorrhagia. Colonoscopy revealed an ulceroinfiltrative lesion that involved rectal mucosa, just above the anal verge. Pathologic examinations demonstrated rectal papillary adenocarcinoma. Neoadjuvant chemotherapy with FOLFOX regimen for 2 courses was started and then, chemotherapy with capecitabine and radiotherapy.

The patient referred to a surgeon, but he postponed it and 75 days later, underwent abdominoperineal resection (APR). Sampling from lymph nodes proved metastasis (T₃N₁), so chemotherapy was continued with FOLFIRI administration.

Twelve sessions of chemotherapy were effective and the patient's condition became better. Thereafter, he was followed up with different laboratory tests every 3 months and computed tomography-scan if it was needed. About nine months after the last session of chemotherapy, the patient complained of severe pain at the surgery site, which increased by sitting. Laboratory findings included a dramatic rise in Carcinoembryonic antigen (CEA) and Carbohydrate antigen 19-9 (CA 19-9) levels. MRI and pathologic investigations demonstrated tumor invasion to the prostate and pericoccygeal tissues, so prostatectomy was performed. Following the surgery, testicles infection and irritation occurred; thus levofloxacin and cephalexin were administered.

By the next month, bilateral hemorrhagic papulonodular scrotal lesions appeared. The largest one of these burning, painful, and erythematous lesions had a 1 cm diameter.

Corresponding Author: F. Joukar

School of Medicine, Shahid Sadoughi University of Medical Sciences, Yazd, Iran
Tel: +98 913 4541125, Fax: +98 3536236439, E-mail address: joukar.f@ssu.ac.ir

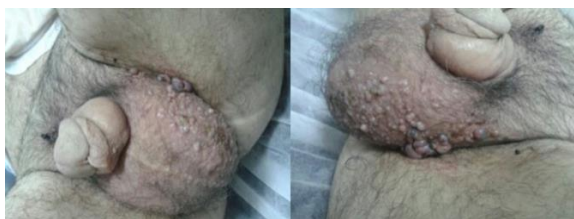

Figure 1. Papulonodular scrotal lesions of metastatic rectal adenocarcinoma.

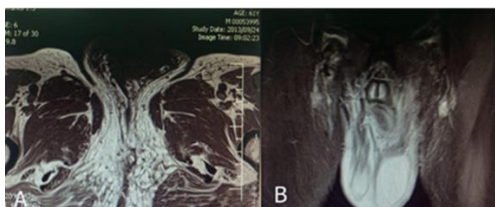


Figure 2. Axial T1W and Coronal T1W FS with the contrast of scrotum show scrotal skin thickening and signal changes as a low signal in T1W and High in T2W (not shown) with enhancement suggestive for scrotal invasion.

Immunostaining for CK 20, CK 7, and CKAE 1/3 confirmed cutaneous metastasis of colonic adenocarcinoma. The patient underwent FOLFIRI-Avastin chemotherapy protocol and radiotherapy. Some of the lesions disappeared, but most of them remained unmodified.

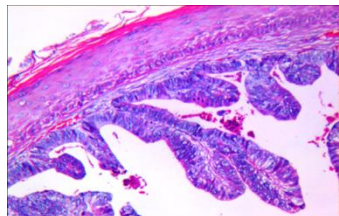


Figure 3. Scrotal skin metastasis from rectal adenocarcinoma (H and E, 4x).

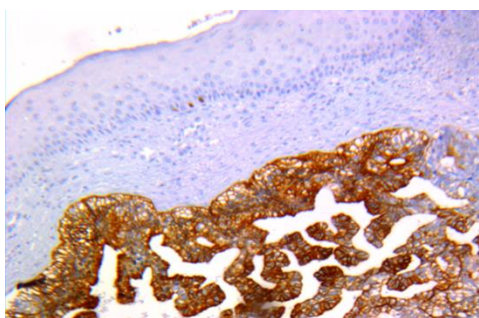


Figure 4. Immunohistochemical staining shows strongly positive expression of CD20 (10x).

Three months later, due to an unexplained headache, MRI was done and revealed 2 well-defined enhancing mass lesions in gray-white matter junction of the right

and left frontal lobes (21*15 mm and 21*19 mm) with prominent peripheral edema suggestive of a metastatic lesion. Radiotherapy was not efficient and finally, the patient expired.

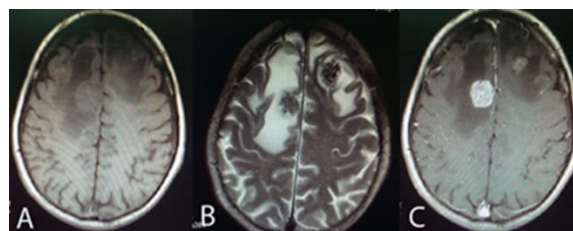


Figure 5. Axial T1W, T2W, and T1W with the contrast of brain reveal two intraaxial mass lesions in both frontal lobes, the intermediate signal in T1W and low signal in T2W with marked enhancement and massive peripheral vasogenic edema, consistent with metastases

Discussion

Breast cancer in women and lung cancer in men are neoplasms that mostly metastasize to the skin. Cutaneous metastasis of internal malignancies occurs in 0.7-9.0% of all malignancies (15,16). Previous studies showed that cutaneous metastasis of rectal cancer mostly occur in the first 3 years of the disease course, and this period is about 4-24 months for scrotal metastasis (17-27). There was also a report of metastatic scrotal nodules 5 months before diagnosis of colorectal carcinoma (28).

Cutaneous metastasis is not only rare, but also implicates its poor prognosis that the median survival is about 20 months (28). Mostly, extensive metastatic diseases cause skin secondary tumors, which are the sign of therapy failure, recurrence, or as the first presentation of occult malignancy (27,29).

Our patient first had a prostate involvement due to tumor recurrence at the surgical site lasting to prostatectomy. Although prostate involvement in rectal cancer is not rare, it has been reported in just one of the similar reported cases. Twenty-one months after completion of the tumor therapy, secondary malignancy showed itself by itchy, erythematous, and hemorrhagic papulonodular lesions on the scrotum. Secondary scrotal tumors occur in several proposed routes, including retrograde venous embolism, retrograde lymphatic extension, arterial embolism, direct invasion along the testicular cord, and transperitoneal seeding through a congenital hydrocele (12,30,31). Scrotal structures are not through the rectal venous and lymphatic drainage pathway; there is no inguinal lymphatic involvement, the scrotum is not in contact with the rectum, so by

Scrotal lesions of metastatic rectal adenocarcinoma

ruling out other possible mechanisms, the metastatic pathway in our case seems to be an arterial embolism.

Overall, brain metastases in patients suffering from cancers are common and gastrointestinal malignancies such as colorectal adenocarcinoma, also are no exception (32). At the time of diagnosis of colorectal cancer, brain involvement might be present in 2-3% of the cases. Additionally, 10% of patients can develop brain metastases during the course of their disease. It is more common in old patients with the mean age of 61.5 and usually occurs about 27 months after the diagnosis of primary cancer (33). Our case developed brain lesions when he was 61-year-old, 24 months after the first diagnosis of colorectal cancer. In a few cases,

calcification of the metastatic brain lesions has been reported, which is more suggestive of a primary brain tumor (34). In between, he complained of a continuous headache, so MRI was performed. Brain metastasis has not been mentioned in any of the colon adenocarcinomas with scrotal metastasis reports which can lead to his death.

Although skin metastasis is rare, it might be the initial manifestation of gastrointestinal malignancies. Also, it must be considered as a differential diagnosis in a patient with colorectal cancer, so serial physical examination is important, and in the case of suspicious lesions, biopsy, and pathologic studies may confirm the diagnosis.

Table 1. Summary of related articles

Author, year	Age	Morphology of tumor origin and stage	Primary cancer treatment	Other sites of metastasis	Clinical manifestation	Medication	Follow-up (months)
Lookingbill et al, 1990(28)	NR	colorectal Adeno	-	-	Nod	NR	NR
Shetty et al, 1988(19)	60	moderately differentiated rectal Adeno	APR	lymph nodes, groin node	multiple Nodes	NR	NR
Boucher et al, 2001(20)	30	colorectal Adeno	NCR+APR	lung	Ulcerated Paps, Plqs	NR	NR
Melis et al, 2002(35)	41	rectal Adeno (stage IV)	NCR	anal sphincter, prostate, hepatic lobes, lymphatic and vascular vessels	erythematous Plqs	NR	NR
Hayashi et al, 2003(21)	50	Rectal Adeno	R	inguinal lymph node	slightly reddish Nods	NR	7
Reuter et al, 2007(22)	69	colorectal Adeno (at least stage IIB)	NCR+ APR	groin, generalized lymphogenic spread	asymptomatic, erythematous soft Plq	NR	6
McWeeney et al, 2009(23)	72	poorly-differentiated Adeno(stage III)	R+ NCR	mesorectal lymph node, liver	Nodes	wide local excision.	NR
Goris Gbenou et al, (36)	79	Rectal Adeno	R	penis, pubis	papulonodules	chemotherapy	6
Balta et al, 2012(24)	46	rectal mucinous Adeno (stage IIIB)	R	left inguinal, perianal region	multiple eroded Nodes/ ulcers	-	NR
Ozgen et al, 2013(25)	65	Rectal Adeno (IIA)	NCR+R	rectal recurrences, spermatic cord	slightly reddish Nodes	CR	12
Udkoff et al, 2016(26)	56	Colonal Adeno	NCR+R	abdomen skin	Paps and Nods	CR	18
Dehal et al, 2016(27)	47	Rectal mucinous Adeno (stage IV)	palliative CR	aortocaval and left inguinal lymphadenopathy, retroperitoneal lymphadenopathy	Nods	Palliative radiation therapy	12
Wu et al, 2016(37)	36	rectal Adeno	APR	penis, liver	Ulcerated Paps, Plqs	Palliative chemotherapy	16
Swofford et al, 2017(29)	54	Adeno	CR	-	mass, necrotic wound, discharge	CR	NR
Moghimi et al, 2017	59	rectal Adeno	NCR+R	prostate, brain	hemorrhagic, erythematous nodulopapular lesions	CR	5

Abdominoperineal resection = APR; Chemoradiation = CR; Neoadjuvant chemoradiotherapy = NCR; Nodules = Nod; Papules= Pap; Plaques=Plq; Not reported= NR; Resection= R

Acknowledgements

The authors would like to appreciate Mr. Mehrdad Rouzbeh for his efforts in finding the patient's images and Dr. Hossein Ahrar for his valuable comments.

References

- Habr-Gama A. Assessment and management of the complete clinical response of rectal cancer to chemoradiotherapy. *Colorectal Dis* 2006;8:21-4.
- Siegel R, Naishadham D, Jemal A. Cancer statistics, 2013. *Cancer J Clin* 2013;63:11-30.
- August DA, Ottow RT, Sugarbaker PH. Clinical perspective of human colorectal cancer metastasis. *Cancer Metastasis Rev* 1984;3:303-24.
- Tonyali O, Sumbul AT, Ozturk MA, Koyuncuer A, Ekiz F. A case of rectal adenocarcinoma presented with palatine tonsil metastasis. *J Oncol Pharmacy Pract* 2014;22:341-3.
- Van Cutsem E, Nordlinger B, Adam R, Kohne CH, Pozzo C, Poston G, et al. Towards a pan-European consensus on the treatment of patients with colorectal liver metastases. *Eur J Cancer* 2006;42:2212-21.
- Hess KR, Varadhachary GR, Taylor SH, Wei W, Raber MN, Lenzi R, et al. Metastatic patterns in adenocarcinoma. *Cancer* 2006;106:1624-33.
- Iiyama T, Watanabe H. Scrotal metastasis from ureteral cancer. *J Urol* 2001;165:1637.
- Aydin GB, Ciftci AO, Yalcin B, Akcoren Z, Caglar M, Senocak ME, et al. Paratesticular metastasis from Wilms tumor associated with a hydrocele. *Pediatr Blood Cancer* 2006;47:97-9.
- Nouhaud FX, Di Fiore F, Noel N, Gobet F, Pfister C. Scrotal metastasis from a nonmuscle-infiltrative bladder cancer: a surprising clinical evolution. *Urology* 2012;80:e37-8.
- Norberg SM, Oros M, Manucha V, Eun D, Bilusic M. Loss of e-cadherin and retinoblastoma genes in a case of urothelial carcinoma with scrotal metastasis. *Can J Urol* 2015;22:7755-7.
- Pichler R, Tulchiner G, Aigner F, Horninger W, Heidegger I. Paratesticular Metastasis of a Clear-Cell Renal-Cell Carcinoma With Renal Vein Thrombus Mimicking Primary Testicular Cancer. *Clin Genit Cancer* 2017;15:e123-e6.
- Leung ST, Chu CY, Lai BM, Cheung FM, Khoo JL. Scrotal wall metastasis as the first manifestation of primary gastric adenocarcinoma. *Hong Kong Med J* 2014;20:70-3.
- Thomas R, Swamy S. Rare case of gastrointestinal stromal tumor presenting with scrotal metastasis. *Ind J Surg* 2015;77:188-9.
- Coussa-Koniski ML, Maalouf PA, Raad NE, Bejjani NA. Scrotal wall metastasis from a primary lung adenocarcinoma. *Respir Med Case Rep* 2015;15:77-9.
- Gates O. Cutaneous Metastases of Malignant Disease. *Am J Cancer* 1937;30:718-30.
- Lookingbill DP, Spangler N, Helm KF. Cutaneous metastases in patients with metastatic carcinoma: a retrospective study of 4020 patients. *J Am Acad Dermatol* 1993;29:228-36.
- Gmitter TL, Dhawan SS, Phillips MG, Wiszniak J. Cutaneous metastases of colonic adenocarcinoma. *Cutis* 1990;46:66-8.
- Reingold IM. Cutaneous metastases from internal carcinoma. *Cancer* 1966;19:162-8.
- Shetty MR, Khan F. Carcinoma of the Rectum with Scrotal Metastases. *Br J Urol* 1988;62:612.
- Boucher KW, Heymann WR. Ulcerated papules of the scrotum. *Arch Dermatol* 2001;137:495-500.
- Hayashi H, Shimizu T, Shimizu H. Scrotal metastases originating from colorectal carcinoma. *Clin Exp Dermatol* 2003;28:226-7.
- Reuter J, Bruckner-Tuderman L, Braun-Falco M. Epidermotropic scrotal metastasis of colorectal cancer. *Int J Color Dis* 2007;22:1133-4.
- McWeeney DM, Martin ST, Ryan RS, Tobbia IN, Donnellan PP, Barry KM. Scrotal metastases from colorectal carcinoma: a case report. *Case J* 2009;2:111.
- Balta I, Vahaboglu G, Karabulut AA, Yetisir F, Astarci M, Gungor E, et al. Cutaneous metastases of rectal mucinous adenocarcinoma mimicking granuloma inguinale. *Int Med* 2012;51:2479-81.
- Ozgen A, Karakaya E, Bozdogan N. Scrotal skin metastasis from rectum adenocarcinoma. *Rare Tumors* 2013;5:e60.
- Udkoff J, Cohen PR. Adenocarcinoma of the colon presenting with scrotal metastasis: case report and review of the literature. *Dermatol Online J* 2016;22:13030.
- Dehal A, Patel S, Kim S, Shapera E, Hussain F. Cutaneous Metastasis of Rectal Cancer: A Case Report and Literature Review. *Perm J* 2016;20:74-8.
- Lookingbill DP, Spangler N, Sexton FM. Skin involvement as the presenting sign of internal carcinoma. A retrospective study of 7316 cancer patients. *J Am Acad Dermatol* 1990;22:19-26.
- Swofford BP, Dragovich T. Sigmoid Adenocarcinoma with Regional Scrotal Metastasis. *Case Rep Oncol* 2017;10:416-9.

Scrotal lesions of metastatic rectal adenocarcinoma

30. Hanash KA, Carney JA, Kelalis PP. Metastatic tumors to testicles: routes of metastasis. *J Urol* 1969;102:465-8.
31. Pienkos EJ, Jablokow VR. Secondary testicular tumors. *Cancer* 1972;30:481-5.
32. Fowler A, Cook R, Biggs M, Little N, Assaad N, McDonald K. Survival of patients following neurosurgical treatment of colorectal adenocarcinoma metastasis in the Northern Sydney-Central Coast area. *J Clin Neurosci* 2008;15:998-1004.
33. Wroński M, Arbit E. Resection of brain metastases from colorectal carcinoma in 73 patients. *Cancer* 1999;85:1677-85.
34. Michail P, Amith I, George S, George MK. A case of calcified metastatic colorectal adenocarcinoma mimicking a benign lesion: pitfalls in diagnosis. *Case Rep Oncol Med* 2015;2015:936260.
35. Melis M, Scintu F, Marongiu L, Mascia R, Frau G, Casula G. Inflammatory cutaneous metastasis from rectal adenocarcinoma: report of a case. *Dis Colon Rectum* 2002;45:562-3.
36. Goris Gbenou MC, Wahidy T, Llinares K, Cracco D, Perrot A, Riquet D. Atypical Phimosis Secondary to a Preputial Metastasis from Rectal Carcinoma. *Case Rep Oncol* 2011;4:542-6.
37. Wu G, Gu BJ, Nastiuk KL, Gu J, Wu DL. Metastasis to scrotal skin as the initial manifestation in a patient with rectal adenocarcinoma: a rare case report and literature review. *Asian J Androl* 2016;18:492-3.